



## Akciğer Kanserini Taklit Eden Gizli Yabancı Cisim

Occult Foreign Body; Mimicking Lung Cancer

Yabancı cisim? Akciğer Kanseri? / Occult Foreign Body? Lung Cancer?

Koray Aydođdu<sup>1</sup>, Göktürk Fındık<sup>1</sup>, Leyla Sağlam<sup>2</sup>, Sadi Kaya<sup>1</sup>

<sup>1</sup>Department of Thoracic Surgery, <sup>2</sup>Department of Chest Disease ,  
Atatürk Chest Disease and Chest Surgery Training and Research Hospital, Ankara ,Turkey.

### Özet

Öksürük, nefes darlığı ve tekrarlayan hemoptizi ile kendini gösteren, astım, kronik bronşit ve akciğer kanserini taklit ederek cerrahi rezeksiyonla sonlanan, bronşial yabancı cisim aspirasyonu olan olgumuzu sunuyoruz. Gizli kalmış yabancı cisim aspirasyonları erişkinlerde nadir görülürler.Olgumuzda olduğu gibi aylarca veya yıllarca tesbit edilemeyebilirler.Bazen bronşa yerleşmiş bir endobronşial lezyonla birlikte olabilen akciğer kanserini taklit edebilir.

### Anahtar Kelimeler

Yabancı Cisim, Aspirasyon, Akciğer Kanseri.

### Abstract

We describe a case of chronical bronchial foreign body presenting with cough, dyspnea and recurrent hemoptysis mimicking asthma, chronic bronchitis and lung cancer and undergoing surgical resection for diagnosis. Occult tracheobronchial foreign body aspirations are infrequently seen in adults. It may be undetected for months to years as in our case. Sometimes it can mimic a lung cancer with an endobronchial lesion placed in the bronchus.

### Keywords

Foreign Body, Aspiration, Lung Cancer.

DOI: 10.4328/JCAM.10.3.21 Received: 24.09.2010 Accepted: 30.01.2010 Printed: 01.09.2010 J.Clin.Anal.Med.2010;1(3):57-59

Corresponding Author: Koray Aydođdu, Department of Thoracic Surgery Atatürk Chest Disease and Chest Surgery Training and Research Hospital Ankara, Turkey. Phone : +090 312 355 21 10 Fax : +90 312 355 1 35 E-mail: dr.k.aydogdu@hotmail.com

## Introduction

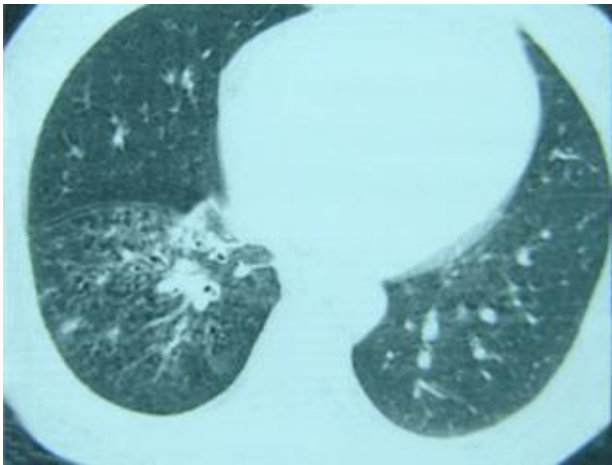
Tracheobronchial foreign body aspiration is a serious problem among all ages, especially in childhood. If it causes a total airway obstruction, it may lead to asphyxia and it is unfortunately a cause of death in childhood. However, it may be asymptomatic for many years or may present with nonspecific respiratory symptoms [1]. Early diagnosis is very important and bronchoscopy is the gold standard for diagnosis. If the diagnosis is in doubt, flexible bronchoscopy can be used to examine more distal parts of the bronchial tree because it excludes a foreign body more than rigid bronchoscopy. However, rigid bronchoscopy plays more role in extracting foreign bodies [2, 3].

## Case

A 35 year old man submitted to our clinic with persistent cough, recurrent fever and intermittent haemoptysis since 2003. He was diagnosed as asthma and chronic bronchitis and treated with bronchodilator and antibiotic drugs for about two years. His symptoms were only slightly relieved but they did not subside.

On physical examination, he had ronchi on the right side of the chest and 37.5 centigrade fever. All the laboratory studies resulted normally except for leucocyte rise.

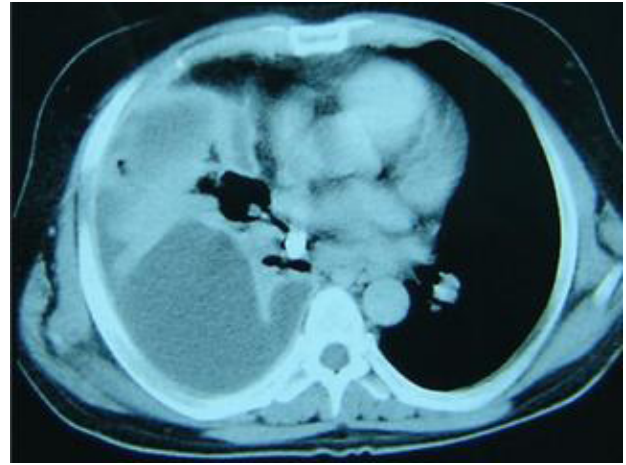
We planned computed tomography [CT] of the thorax and



**Figure 1.** HRCT showed right lower lobe bronchiectasia

it showed right lower lobe bronchiectasis [Figure 1] and pulmonary artery was wider than normal but there was no thrombus in it. There were precarinal, subcarinal and right hilar calcific lymph nodes and a right sided pleural effusion. [Figure 2]. Fiberoptic bronchoscopy was performed and an endobronchial lesion (EBL) was seen on the entrance of the right lower lobe bronchus and bronchoalveolar lavage was taken and histopathological examinations yielded squamous metaplasia.

So it was doubtful whether the endobronchial lesion was malignant or not. Herein we planned a rigid bronchoscopy to utilize the EBL better. During rigid bronchoscopy we tried to obtain much more biopsy material but we could not manage, because it was as hard as bone. So we sus-



**Figure 2.** Thorax dynamic computerised tomography shows wider arteria pulmonalis was without trombus in it. There is precarinal, subcarinal and right hiler calcified lymph nodes, and pleural effusion on the right side.

pected whether it might be a foreign body or not.

With a detailed history we learned that, he had aspirated a tooth during extraction about 3 years ago which was thought to be swallowed and caused no symptoms of aspiration. His symptoms had begun about two or three months after the extraction of tooth and lasted for three years.

It was obvious that the reason of the symptoms and radiological findings was the aspirated tooth. So an operation was planned. Right thoracotomy and right lower lobectomy was performed. The necessity of lobectomy was bronchiectasis that caused bronchial obstruction.

## Discussion

Tracheobronchial foreign body aspiration is a common problem in childhood especially those below the age of 3 years and it is infrequently seen in adults [4]. In the adult population, such aspiration is most commonly secondary to unconscious accidental ingestion during general anesthesia, sedation, intoxication, seizures or neurologic disorders affecting the oropharynx. It was found that the foreign body aspiration resulting from dental surgery accidents is more common in adults, so foreign body aspiration can occur in the absence of any predisposing factor.[5]. In fact, the factors predisposing to foreign body aspiration and the type of aspirated object are affected by geographic and cultural differences. Throughout the world, the types and aspiration ratios of aspirated foreign bodies change according to nutritional habits, socio-economic status, culture and the traditions and customs of the people [5]. The foreign bodies include stone, tooth fragments, bone fragments, nuts, seeds and needle. A comprehensive study carried out in Turkey showed that the most commonly aspirated foreign body is the turban pin, which is consistent with our experience during the fixation of the turban, the neck is extended and the pins are held between the lips. Meanwhile speech or laughter can cause the deep aspiration of the pin into the tracheobronchial system [2,3,5].

In adults, aspirated foreign bodies generally localize on the right bronchus because of the anatomic angle but it may be localized in both bronchi with the same ratio in children.

Sometimes the parents or patients themselves easily notice the symptoms [6]. Clinical manifestations are nonspecific. Main symptoms are cough, dyspnea and wheezing. Cough changes in character according to the movement of aspirated body, irritation and edema in the bronchus. On physical examination; dyspnea, stridor, wheezing, decreased or abnormal breath sounds and fever are the most common signs [1]. It can be misdiagnosed as asthma, chronic bronchitis, pneumonia or croup [1]. Sometimes it can mimic lung cancer [7,8,9]. Our patient had no history of aspiration symptoms after tooth extraction. When his complaints began, he was misdiagnosed as asthma and chronic bronchitis and treated with bronchodilator and antibiotic drugs for years. He underwent bronchoscopy twice and an EBL was seen and biopsy was performed.

With pathological studies it was diagnosed as lung cancer. We performed rigid bronchoscopy to utilize EBL better. We recognised that it was a foreign body as hard as bone. So he underwent surgery.

For the diagnosis, radiological techniques such as posterior-anterior chest radiographs and CT can be used. If the diagnosis is in doubt, flexible bronchoscopy can be used to examine more distal parts of the bronchial tree. However, rigid bronchoscopy plays more role in extracting foreign bodies [2,3].

The main complications and necessity of thoracotomy in foreign body aspiration are generally pneumothorax, pneumomediastinum, atelectasia, and lung abscess [10].

In conclusion, tracheobronchial foreign body aspiration may be asymptomatic or misdiagnosed as asthma and chronic bronchitis. Aspirated foreign body can lead to bronchiectasis with a bronchial obstruction. Finally bronchiectasis necessitates a thoracotomy and lobectomy.

## References

1. T illiard T, Sim R, Saunders M, Hewer SL, Henderson J. Delayed diagnosis of foreign body aspiration in children. *Emerg Med J.* 2003;20(1):100-1.
2. Kiyani G, Uygun I, Karadag B, Tugtepe H, Iskit SH, Dagli TE. Foreign body aspiration in children, *Kulak Burun Bogaz Ihtis Derg.* 2004;12(5-6):128-33.
3. Yilmaz A, Akkaya E, Damadoglu E, Gungor S. Occult bronchial foreign body aspiration in adults: analysis of four cases. *Respirology.* 2004;9(4):561-3.
4. Lai YF, Wong SL, Chao TY, Lin AS. Bronchial foreign bodies in adults. *J Formos Med Assoc.* 1996;95(3):213-7.
5. Karapolat S, Foreign-body aspiration in an adult. *Can J Surg.* 2008;51(5):411; author reply 411-2..
6. Dikensoy O, Usalan C, Filiz A. Foreign body aspiration: clinical utility of flexible bronchoscopy. *Postgrad Med J.* 2002;78(921):399-403.
7. Ochmanski W, Krawczyk K. [Foreign body imitating bronchial neoplasm] *Przegl Lek.* 1997;54(1):70-2.
8. Nigam BK. Bronchial foreign body masquerading as a lung carcinoma. *Indian J Chest Dis Allied Sci.* 1990; 32 (1):43-7.
9. Sharma M, Lewis C, Lewis ME, Marzouk JF. Prawns masquerading as endobronchial tumours. *Respiration.* 2006;73(6):826-9.
10. Grigoriu BD, Leroy S, Marquette CH. Tracheo-bronchial foreign bodies. *Rev Med Chir Soc Med Nat Iasi.* 2004; 108(4):747-52