

## Evaluation of Vacuum-assisted stereotactic biopsy for isolated BI-RADS 4 microcalcifications

VASB for isolated BI-RADS 4 microcalcifications

Esra Ummuhan Mermi Yetis<sup>1</sup>, Alev Ozturk Gunaldi<sup>1</sup>, Mehmet Mahir Atasoy<sup>1</sup>, Levent Celik<sup>2</sup><sup>1</sup>Department of Radiology, Maltepe University Faculty of Medicine<sup>2</sup>Department of Radiology, Radiologica Imaging Center, İstanbul, Turkey

### Abstract

**Aim:** The aim of this study was to evaluate the long-term results of vacuum-assisted stereotactic biopsy (VASB) for microcalcifications with isolated Breast Imaging Reporting and Data System (BI-RADS 4).

**Material and Methods:** Three hundred sixty-seven patients who underwent VASB due to microcalcifications between June 2011 and October 2017 were screened. VASB was performed in all patients using stereotaxy in the lateral decubitus position. VASB, surgical pathology results and long-term follow-up findings were evaluated. Statistical analysis was evaluated with mean values and underestimation rates.

**Results:** Among 76 patients and 78 microcalcifications, 20 were defined as ductal carcinoma in-situ (DCIS), two were defined as atypical lobular hyperplasia (ALH), one as atypical ductal hyperplasia (ADH) and 56 as benign. The two cases reported as ALH in VASB refused the operation and were followed up, and no progression was detected in their follow-up. The DCIS underestimation rate was 20% (4/20). The mean follow-up time was 55.46 months, and the mean follow-up time in benign lesions was 53.4 months. No conversion to malignancy was detected in any of the patients whose VASB results were found benign (false negative rate 0%).

**Discussion:** In our study, no conversion to malignancy was detected in the long-term follow-up results of patients with isolated BI-RADS 4 microcalcification and having benign VASB results (false negative rate 0%). This method eliminated the necessity of surgical excision in 71.7% (56/78) of the cases with isolated BI-RADS 4 microcalcification in our study. VASB may be the standard method for BI-RADS 4 microcalcifications.

### Keywords

BI-RADS 4; Mammography; Microcalcification; VASB; DCIS

DOI: 10.4328/ACAM.20507 Received: 2021-01-27 Accepted: 2021-03-06 Published Online: 2021-03-18 Printed: 2021-08-15 Ann Clin Anal Med 2021;12(Suppl 3): S250-253

Corresponding Author: Esra Ummuhan Mermi Yetis, Department of Radiology, Maltepe University Faculty of Medicine 34844, Maltepe, İstanbul, Turkey.

E-mail: mdesramermiyetis@gmail.com P: +90 364 219 30 00 F: +90 364 223 30 30

Corresponding Author ORCID ID: <https://orcid.org/0000-0001-6410-590X>

## Introduction

The detection of non-palpable breast lesions has increased with the increase in the number of mammography screening. Microcalcifications are detected in approximately one-third of screening mammograms [1]. It has been reported that approximately 55% of non-palpable breast cancers are associated with calcifications; 55% of the suspicious lesions detected in mammography are isolated microcalcifications [2]. Approximately 80% of ductal carcinoma in situ (DCIS) can only be detected as microcalcification on mammography [3].

Suspected microcalcifications can be surgically removed after wire marking. However, in some studies, it was found that 76-81% of patients who underwent surgical excision had benign pathology [4]. Noninvasive methods such as core biopsy have been increasingly preferred recently due to low cost and morbidity [5].

Vacuum-Assisted Breast Biopsy (VABB) is superior to breast core biopsy due to its advantages, such as the capacity to obtain larger volumes of the specimen, obtaining a greater number of microcalcifications, decreased low cancer prediction rates and reduced sampling error [6]. The needle size in VABB systems ranges from 7 gauge to 14 gauge [7].

Vacuum-assisted stereotactic biopsy (VASB) is increasingly used for the diagnosis of suspected microcalcifications. When performed by experienced radiologists, the false negative rate of the VASB procedure can be as low as 0.6% [8]. Suspected isolated microcalcifications can be sampled by stereotaxy. Breast Imaging Reporting and Data System (BI-RADS) 5 microcalcifications should undergo surgical excision in all cases with accompanying mass, and structural distortion. Surgical intervention can be avoided in most patients with the routine use of VASB before considering more invasive methods for BI-RADS 4 microcalcifications [9]. The purpose of this study is to evaluate the long-term results of VASB for isolated BI-RADS 4 microcalcifications that were previously observed in the middle term.

## Material and Methods

Before each VASB, potential risks and benefits were explained in detail, and informed written consent was obtained from each patient. Ethics committee approval dated 29.07.2020 numbered 2020/900/64 was obtained.

### Patient selection

Patients who underwent VASB between June 2011 and October 2017 were retrospectively screened using the picture archiving and communication system (PACS). A total of 373 microcalcifications were detected in 367 patients. Twenty-nine patients were excluded from the study because they had BI-RADS 5 microcalcifications, 19 patients were excluded because of the accompanying mass, and 44 patients were excluded because of additional findings such as asymmetric density and parenchymal distortion. One hundred ninety-nine patients without long-term follow-up were excluded from the study. A total of 76 patients and 78 microcalcifications were included in the study (Figure 1). Two patients had bilateral breast calcifications.

Each patient included in the study had an initial breast USG evaluation that did not show any abnormalities. Long-term

follow-up was considered as over 30 months. Patients with regular follow-up for 30 months or more (30-102 months) were included in the study.

### Evaluation of the images

Microcalcifications in the initial mammography were classified by two radiologists unanimously, both with more than 10 years of experience (over 1500 mammograms per year). Classification of microcalcifications was made according to the currently available American College of Radiology (ACR) "Breast Imaging Reporting and Data System (BI-RADS) 5th edition" criteria. The most recent BI-RADS lexicon has removed the BI-RADS 3 microcalcification group from the classification due to its wide range of malignancy rates [9, 10]. Lesions were classified as suspicious BI-RADS 4 (A, B, C) or BI-RADS 5 having a high risk of malignancy. For those who had previous mammography films, the decision was made based on interval evaluation.

Patients with BI-RADS 5 microcalcifications were suggested to perform surgical biopsy or VASB, stating that the benign pathology result would not eliminate the need for surgical excision. However, VASB was performed for all patients with BI-RADS 4 microcalcifications.

### Biopsy procedure

All VASB procedures were routinely performed on a lateral decubitus platform with a full-field digital mammography system (Amulet, Fujifilm, Tokyo, Japan) using a 10-gauge VACORA™ Breast Biopsy System (Bard Biopsy Systems, Tempe, Arizona, USA). All patients were placed in the lateral decubitus position. Patients were positioned so that a 5 x 5 cm biopsy window was suitable for the localization of the lesion, following the application of compression with ML projection. The target lesion was determined by scout image and two 15° stereotactic views. Local anesthesia was applied using 5 mL of 2% lidocaine just before the 10-gauge needle was placed in the center of the lesion. A second stereotactic image was taken to confirm the position of the needle. The same steps were repeated when more than one lesion was targeted. Eight biopsy specimens were routinely obtained and the procedure was completed when microcalcifications were detected in these specimens. In all patients, the target breast tissue was checked through the biopsy window before releasing compression; if the microcalcifications did not decrease, the procedure continued to take additional samples. If microcalcifications are still observed after eight biopsies, additional four specimens were taken and the procedure was terminated with a total of 12 specimens. As a result, it was ensured that all patients had microcalcifications in their biopsy specimens. Prior to completion of the procedure, a radiopaque marking clip was left in the biopsy cavity, and if all calcifications were removed, a final check was performed with a mammogram to verify the clip localization (Figure 2). Tissue samples were then placed in formol and sent to the pathology laboratory. Biopsy specimens were imaged with 25 kV and 10 mA exposure factors using the same digital mammography at the end of the procedure. None of the patients required a repeat biopsy.

### Follow-up

The surgical operation was suggested for all patients whose VASB pathology result was atypical and was considered as premalignant. Follow-up was recommended for those with

benign pathology results. Long-term follow-up was accepted as 30 months or more. Follow-up mammograms, breast ultrasonography and breast MRI findings of the patients, if any, were evaluated. Based on follow-up data, histological underestimation or false negative result rate was evaluated.

**Statistical analysis**

False negativity was accepted as the final pathological decision of the lesion with benign pathology by the VASB procedure as malignant/premalignant.

The false-negativity rate was calculated by dividing the number of false-negative lesions by the total number of VASBs.

Histological underestimation was defined as the emergence of invasive carcinoma after surgical excision in cases with DCIS as a result of the biopsy and DCIS or invasive carcinoma in cases with atypia.

Underestimation rate was calculated by dividing the number of underestimated lesions by the total number of lesions with ADH or DCIS determined after VASB.

The data were recorded in a spreadsheet on the computer, and then simple descriptive statistics were made using appropriate software (Excel; Microsoft, Redmond, Washington, USA) for analysis.

**Results**

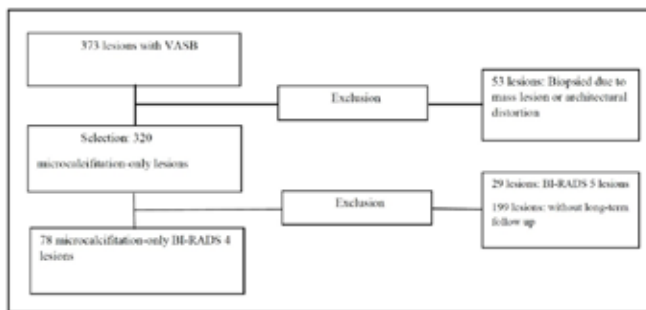
Seventy-eight microcalcifications were evaluated in a total of 76 patients (median age 52.7, range 40-83). The BI-RADS Category and pathology results of microcalcifications are shown in Table 1.

Among 78 microcalcifications in VASB, 20 were defined as DCIS, two of them were ALH, one of them was ADH, and 56 of them were benign. Operation was suggested for two ALH patients. The patients did not want the operation and wanted to be followed. No significant interval change was found during the follow-up. One patient diagnosed with ADH was operated on. In this patient, no malignancy was detected in the postoperative pathology (underestimation rate 0%). All cases with the result of DCIS were operated. In the postoperative pathology, an invasive component was observed in 4 patients, one case evaluated as DCIS in VASB was reported as LCIS postoperatively. No residual tumor was observed in any patient after the operation. There was no recurrence in their follow-up.

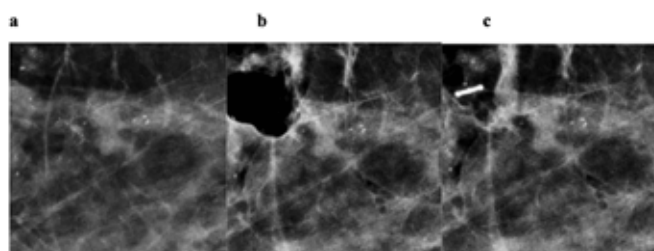
All patients with benign VASB results were followed, none of them converted to malignancy during the follow-up (false negative rate 0%).

Benign cases were in the BI-RADS Category 4A or 4B group. The DCIS underestimation rate was 20% (4/20). The underestimation rate for BI-RADS 4C lesions was 15% (3/20). The follow-up period was at least 31 months (31-102 months). The average follow-up time was 55.46 months. Six-month

follow-up data were available for all benign lesions. There were no additional cases of malignancy after a mean follow-up of 53.4 months for benign lesions. According to the follow-up results, the false negativity rate was 0%.



**Figure 1.** Flow chart showing the formation of the study group. VASB, vacuum-assisted stereotactic biopsy.



**Figure 2.** a–c. BI-RADS 4A microcalcifications (a) were detected at the right breast of a 46-year-old woman. After VASB procedure with a 10-gauge needle, microcalcifications were removed and air (b) is seen at the biopsy site. A radiopaque marking clip (c) is released, so that possible subsequent operations can be easily planned if required.

**Discussion**

Recently, with the increasing use of mammography screening, the detection of non-palpable breast lesions and biopsy requirements have increased. Microcalcifications may be the only finding in early-stage non-palpable breast cancer [11]. Needle-localized surgical biopsy (MLSB), an excisional biopsy from the suspected lesion, is considered the gold standard. However, due to the scarring, high cost and morbidity of this method, non-invasive methods are increasingly used. Lesions detected on mammography alone require stereotactic guidance, and vacuum-assisted breast biopsy (VABB) is currently the preferred biopsy method for stereotactic biopsies [12]. VABB is a fast and effective biopsy technique that can be tolerated by patients, without major complications. VABB has sufficient sensitivity and specificity for diagnosis. VABB often allows complete removal of the mammographic lesion [12]. With the routine use of VASB for BI-RADS 4 microcalcifications, unnecessary surgical excision can be avoided in many patients. In our study, according to the long-term results, the false negativity rate was 0%, as in our study, where we evaluated the mid-term results. Additionally, an average underestimate rate for DCIS was acceptable. While no malignancy was detected in one of our ADH patients after the operation, two ALH patients did not accept the operation and wanted to be followed up with routine mammosonography and MRI. The number of patients with the atypical pathological diagnosis was not sufficient.

**Table 1.** Histologic results with VASB according to the BI-RADS categories

BI-RADS	n	VASB results			
		IDC	DCIS	ALH/ADH	Benign
4A	59		6	2	51
4B	10		5	1	4
4C	9		9		

ADH underestimation rates in the range of 0% to 88% have been reported for stereotactic biopsy techniques [13, 14]. There is one ADH case in our study, and we have few cases to make a reliable interpretation. In the literature, underestimate rates for cancer and DCIS vary between 10% and 30% [15, 16]. The underestimate rate in our patients diagnosed with DCIS was 20% and was similar to the literature.

Our study showed that VASB can be used as a first-line diagnostic approach for isolated BI-RADS 4 microcalcifications. Patients with benign VASB results can be followed up safely. In our study, VASB eliminated the necessity of surgical excision in 71.7% of cases with isolated BI-RADS 4 microcalcification. Failure to detect sufficient calcification in specimen radiograms, failure to detect calcium crystals in histopathological analysis, radiological-histological incompatibility or their combination may be the causes of missed cancer cases. The false negative rate for malignancy was zero in our study. This may be due to the experience of our radiologists, confirmation of the presence of microcalcifications in all included sample radiograms, and radiological-histopathological teamwork [17]. The experience of the radiologist and ensuring the use of specimens containing micro calcification should be considered when establishing guidelines for the VASB procedure.

Excisional biopsy may reduce the chance of sentinel lymph node sampling if the lesion is malignant. After VASB, the biopsy site is intact and preserves the opportunity for sentinel lymph node sampling when necessary. In lesions that can only be detected on mammography, VASB can replace NLSB.

Acceptable false-negative rates of VASB have been reported by experienced radiologists [17]. Radiologists may experience difficulties during follow-up due to scarring and structural deterioration after surgical excision. VASB provides better cosmetic results compared to surgical procedures. VASB is a process with lower cost, less morbidity and takes a short time. In necessary cases, the radiopaque marking clip is also left, and the next operations can be easily planned if necessary.

The use of a lateral decubitus table for VASB has some advantages over prone table systems. Microcalcifications have a higher resolution and provide a high contrast image. It can be performed in the same unit as mammography. Easier access is provided for deep lesions close to the axilla.

There were some limitations in our study. The number of patients with atypia pathology was low, and some patients did not accept the operation and wanted to be followed. We have a small number of patients and we think that larger series with long-term regular follow-up will contribute significantly to the literature.

In conclusion, in our study, the need for surgical excision was eliminated in 71.7% of patients with isolated BI-RADS 4 microcalcifications. According to the long-term results, the false negative rate was 0%. The average underestimation rate for DCIS patients was 20%.

In the presence of experienced radiologists, VASB is a fast and effective method, does not cause major complications and it can be used as the first choice for isolated BI-RADS 4 microcalcifications.

#### Scientific Responsibility Statement

The authors declare that they are responsible for the article's scientific content including study design, data collection, analysis and interpretation, writing, some of the main line, or all of the preparation and scientific review of the contents and approval of the final version of the article.

#### Animal and human rights statement

All procedures performed in this study were in accordance with the ethical standards of the institutional and/or national research committee and with the 1964 Helsinki declaration and its later amendments or comparable ethical standards. No animal or human studies were carried out by the authors for this article.

#### Funding: None

#### Conflict of interest

None of the authors received any type of financial support that could be considered potential conflict of interest regarding the manuscript or its submission.

#### References

- İflazoğlu N, Üreyen O, Atahan MK, Meral UM, Sezgin G, Tarcan E. A Retrospective Comparative Study of Image-Guided Excisional Biopsy in High-Risk Non-Palpable Breast Lesions: Predictive Factors for Malignancy. *J Breast Health*. 2015; 11(3):132-7.
- Taskin F, Kalayci CB, Tuncbilek N, Soydemir E, Kurt N, Kaya H, et al. The value of MRI contrast enhancement in biopsy decision of suspicious mammographic microcalcifications: a prospective multicenter study. *Eur Radiol*. 2021; 31(3):1718-26. DOI: 10.1007/s00330-020-07265-y.
- Bluekens AM, Holland R, Karssemeijer N, Broeders MJ, den Heeten GJ. Comparison of digital screening mammography and screen-film mammography in the early detection of clinically relevant cancers: a multicenter study. *Radiology*. 2012; 265(3):707-14.
- Kuehner G, Darbinian J, Habel L, Axelsson K, Butler S, Chang S, et al. Benign Papillary Breast Mass Lesions: Favorable Outcomes with Surgical Excision or Imaging Surveillance. *Ann Surg Oncol*. 2019;26(6):1695-1703.
- Huang ML, Hess K, Candelaria RP, Eghtedari M, Adrada BE, Sneige N, et al. Comparison of the accuracy of US-guided biopsy of breast masses performed with 14-gauge, 16-gauge and 18-gauge automated cutting needle biopsy devices, and review of the literature. *Eur Radiol*. 2017; 27(7):2928-33.
- Liu J, Huang L. Image-guided vacuum-assisted breast biopsy in the diagnosis of breast microcalcifications. *J Int Med Res*. 2018;46(7):2743-53.
- den Dekker BM, van Diest PJ, de Waard SN, Verkooijen HM, Pijnappel RM. Stereotactic 9-gauge vacuum-assisted breast biopsy, how many specimens are needed? *Eur J Radiol*. 2019;120:108665. DOI: 10.1016/j.ejrad.2019.108665
- Atasoy MM, Tasali N, Çubuk R, Narin B, Deveci U, Yener N, et al. Vacuum-assisted stereotactic biopsy for isolated BI-RADS 4 microcalcifications: evaluation with histopathology and midterm follow-up results. *Diagn Interv Radiol*. 2015;21(1):22-7.
- Bennani-Baiti B, Baltzer PA. MR Imaging for Diagnosis of Malignancy in Mammographic Microcalcifications: A Systematic Review and Meta-Analysis. *Radiology*. 2017; 283(3):692-701.
- Fowler EE, Sellers TA, Lu B, Heine JJ. Breast Imaging Reporting and Data System (BI-RADS) breast composition descriptors: automated measurement development for full field digital mammography. *Med Phys*. 2013;40(11):113502. DOI: 10.1118/1.4824319.
- Lei C, Wei W, Liu Z, Xiong Q, Yang C, Yang M, et al. Mammography-based radiomic analysis for predicting benign BI-RADS category 4 calcifications. *Eur J Radiol*. 2019; 121:108711.
- Esen G, Tutar B, Uras C, Calay Z, İnce Ü, Tutar O. Vacuum-assisted stereotactic breast biopsy in the diagnosis and management of suspicious microcalcifications. *Diagn Interv Radiol*. 2016; 22(4):326-33.
- Tozbikian G, George M, Zynger DL. Diagnostic terminology used to describe atypia on breast core needle biopsy: correlation with excision and upgrade rates. *Diagn Pathol*. 2019;14(1):69.
- Grady I, Gorsuch H, Wilburn-Bailey S. Ultrasound-guided, vacuum-assisted, percutaneous excision of breast lesions: an accurate technique in the diagnosis of atypical ductal hyperplasia. *J Am Coll Surg*. 2005;201(1):14-7.
- Park SH, Kim MJ, Kim SJ, Kim EK. Ductal carcinoma in situ diagnosed using an ultrasound-guided 14-gauge core needle biopsy of breast masses: can underestimation be predicted preoperatively? *Ultrasonography*. 2014;33(2):128-35.
- Kim YM, Park HB, Ryu JW. Usefulness of ultrasound-guided mammotome biopsy for microcalcification. *J Korean Radiol Soc*. 2005; 53:129-35.
- Gümüş H, Gümüş M, Devalia H, Mills P, Fish D, Jones P, et al. Causes of failure in removing calcium in microcalcification-only lesions using 11-gauge stereotactic vacuum-assisted breast biopsy. *Diagn Interv Radiol*. 2012; 18(4):354-9.

#### How to cite this article:

Esra Ummuhan Mermi Yetis, Alev Ozturk Gunaldi, Mehmet Mahir Atasoy, Levent Celik. Evaluation of Vacuum-assisted stereotactic biopsy for isolated BI-RADS 4 microcalcifications. *Ann Clin Anal Med* 2021;12(Suppl 3): S250-253